



**Non-Arthroplasty  
Hip Registry**

# **Patient Hip Information**

---

Rob Lawton & Ajay Malviya

# **A Guide for Patients with Hip and Groin Pain**

**By - Rob Lawton & Ajay Malviya**

## **Overview**

- Introduction
- Hip Anatomy
- Is the pain coming from the hip joint?
- Intra-articular causes of hip pain
  - Impingement
  - Dysplasia
  - Arthritis
- Extra-articular causes of hip pain
  - Trochanteric Pain Syndrome
  - Snapping Hip Syndromes
  - Deep Gluteal Pain Syndrome
  - Adductor Tendinopathy & Pubic Symphysis
  - Sports Injuries
- Conclusions
- References

## **Introduction**

The following is written for patients who are being investigated by their doctor for pain in or around the hip joint. It is not an exhaustive explanation of all hip problems, but an introduction to common causes of hip pain and how they are diagnosed.

Many people have relatives or friends who have undergone a hip replacement. This is a successful treatment for chronic hip joint pain, such as that caused by osteoarthritis, where the internal cartilage lining of the joint has been worn away.

However, no replacement joint so far developed is as good as a well functioning natural joint and all replacement joints have a risk of wearing out, especially in younger and active patients, who may then need a replacement of the replacement.

Replacement of a replacement joint is termed “revision” surgery and is more technically demanding for the surgeon and more risky for the patient than initial replacement of a natural hip. Hence modern philosophy in the management of hip problems is to identify symptoms early, to see if anything can be done repair the joint and/or prevent further damage in order to relieve symptoms and slow down the progress to arthritis, preserving the patient’s natural joint for as long as possible.

Key-hole surgery (arthroscopy) to repair and reshape the inside of the hip joint, and bone realignment (osteotomy) to change the orientation of the socket or thigh bone are the main techniques used to protect and preserve the natural hip joint.

### **Hip Anatomy**

You probably know that the hip is a ball and socket joint. What you may not know is that the hip socket also has a soft cartilage rim, called the labrum. This rim makes the socket slightly deeper, helps to keep the ball shaped head of the femur (thigh bone) in the acetabulum (socket), and also keeps the joint lubricating fluid in place.

**Fig 1a. Diagram of the right hip ball and socket joint, with the head of the femur dislocated to reveal the articular joint surfaces.**

# Hip Joint

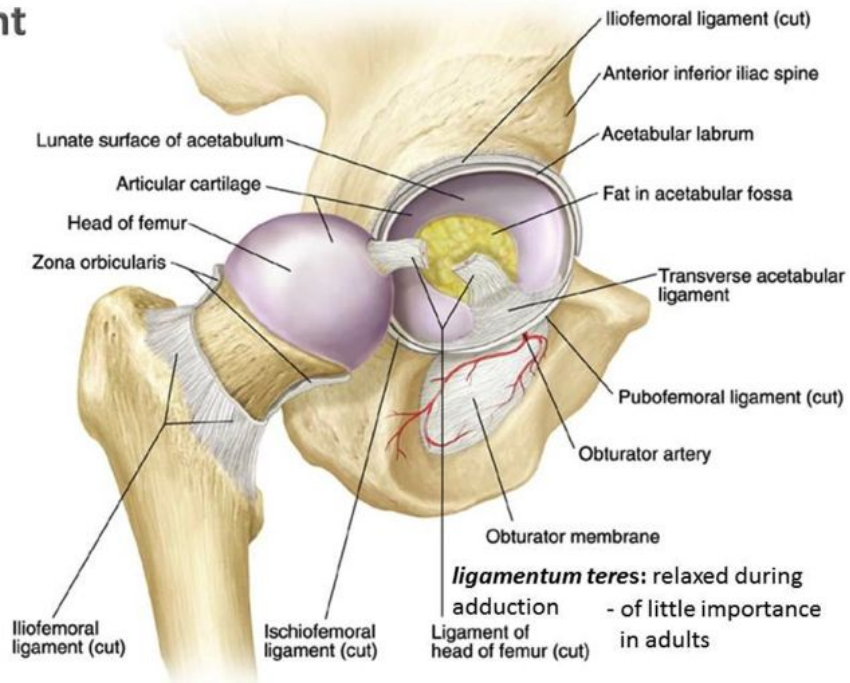
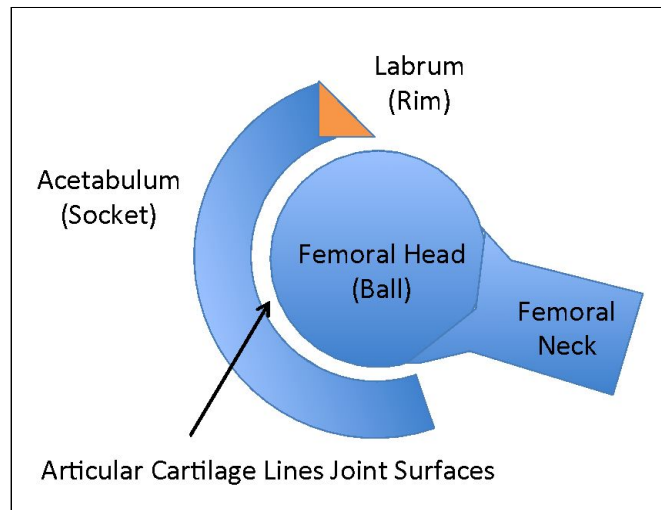


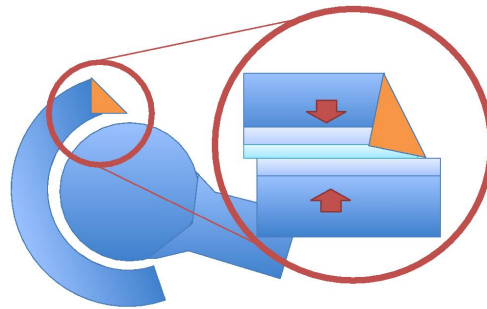
Fig 1b. Schematic axial representation (as if the patient is lying down on their back and the hip joint is viewed from below) of the left hip joint, showing femoral head, acetabulum, anterior acetabular labrum and articular cartilage.



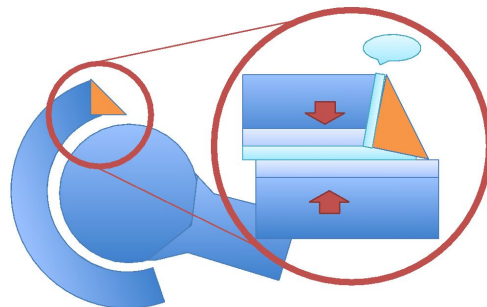
Often the first sign of a problem with the hip is a tear in the cartilage rim (labral tear), which it thought to allow the lubricating fluid to leak out. Without lubricating fluid, the joint is more vulnerable to wear and tear damage that leads to arthritis.

The joint reacts by making more fluid, which causes swelling and pain. The torn labrum can also click or catch (although most commonly clicking around the hip joint is due to tendons outside the hip, rather than anything inside the hip joint itself).

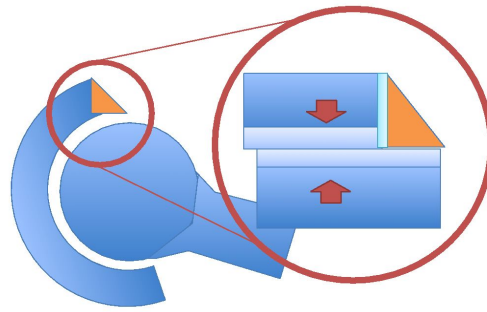
**Fig 2 a. Axial view of normal labral function producing a seal at that helps keep synovial fluid (joint lubricating fluid) in position when the cartilage is loaded.**



**Fig. 2b. Axial view of labral tear at junction between labrum and acetabulum, which allows synovial fluid to escape.**

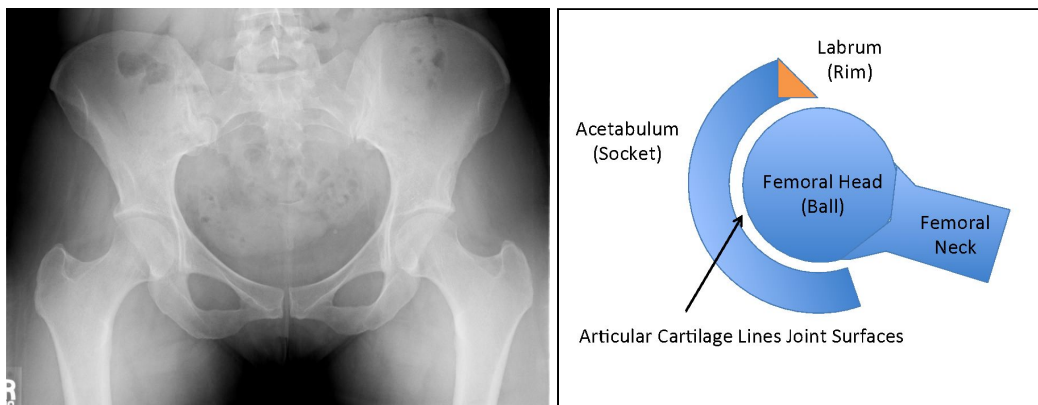


**Fig. 2c. Lack of lubricating synovial fluid results in altered loading of articular cartilage during weight-bearing activities.**

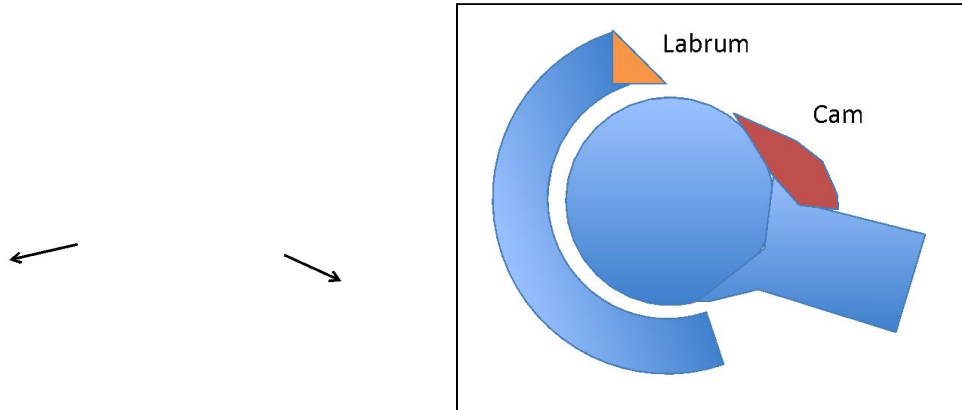


Not all people have the same type of hip anatomy. There is natural variation in both the shape and orientation of the femoral head and neck and in the shape and orientation of the acetabulum. The commonest variations are referred to as “cam” when the femoral head is shaped like slightly more oval than a perfect sphere; “Pincer”, where the socket is slightly deeper so that the rim of the socket can pinch the neck of the femur and “dysplasia” where the socket is shallow. Pincer pathology can also occur when the socket is not particularly deeper, but not orientated in the ideal direction, typically pointing slightly too far backwards, termed “retroversion”. In some cases these variations may be a result of childhood hip disorders such as slipped upper femoral epiphysis (SUFE), Perthes’ Disease or childhood dysplasia.

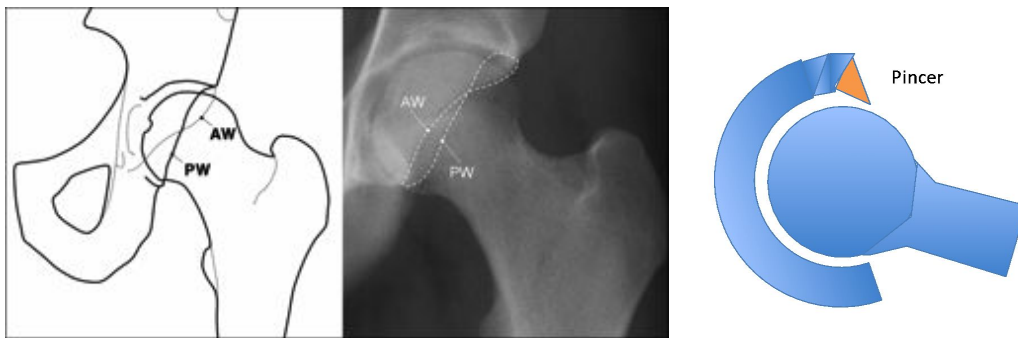
**Fig. 3 a. Normal AP pelvis x-ray and axial schematic view of normal hip.**



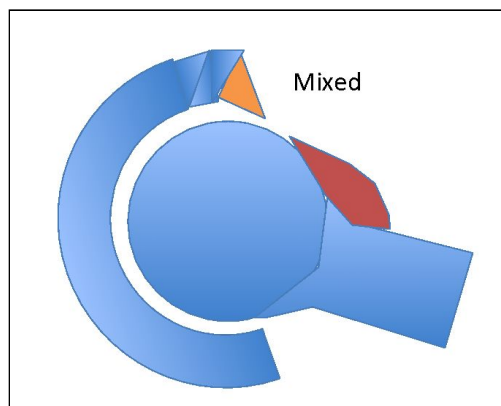
**Fig. 3b. X- ray of bilateral cam deformities and axial schematic of cam deformity.**



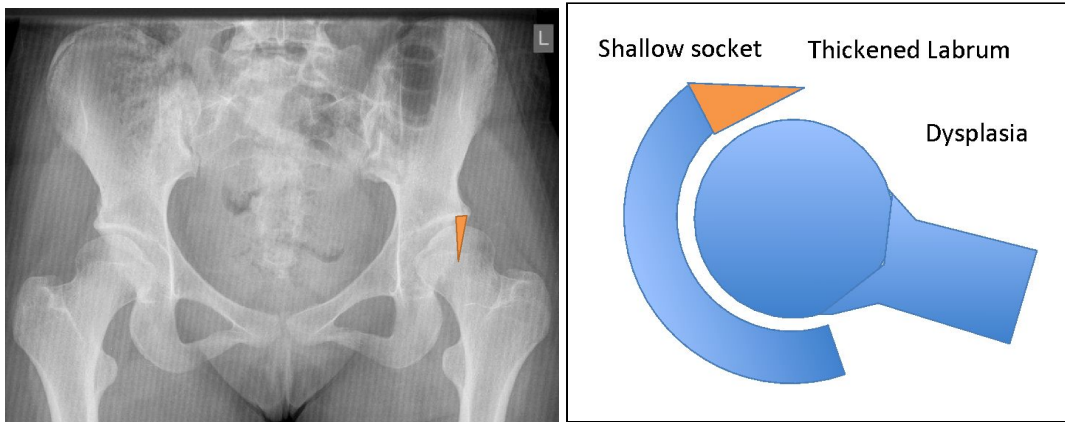
**Fig. 3 c. AP diagram and X Ray of acetabular retroversion causing pincer type impingement. Cross-over of the anterior and posterior walls is illustrated in the diagram and x-ray. Increased anterior coverage is shown in the axial schematic representation.**



**Fig. 3 d. Axial schematic representation of a mixed impingement with pincer increased acetabular coverage and femoral cam deformity.**



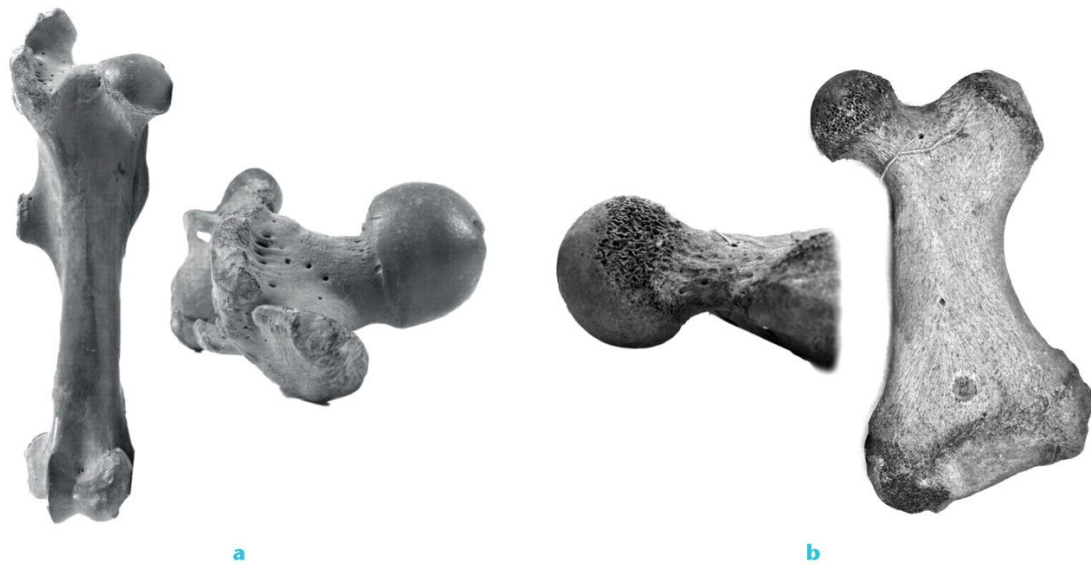
**Fig 3 e. X ray of bilateral hip dysplasia, with reduced superior bony coverage in the superior weight-bearing zone illustrated by the orange segment of the left hip. The axial schematic representation illustrates the typical finding of a shallow acetabulum and a thickened hypertrophic labrum.**



Interestingly, the reasons for this degree of variation may be related to evolution. Running mammals have more oval shaped hips that move well forwards and back, but not as much from side to side or in rotation. Swimming and climbing mammals have rounder hips with a shallow socket that move well in all directions. Human hips are somewhere in between. Some studies have reported a higher proportion of cam shaped hips among athletes than the general population and it may be that a cam shape is advantageous for running. The hip shape we develop as adults is probably related to a combination of our genes and our activities during growth. However, considerable variation is seen, even among asymptomatic individuals, and more research is needed before we can be sure about the reasons for observed variations.

**Fig. 4. Horse and walrus femora (thigh bones) showing variation in femoral head (hip ball) shape. The asymmetric more “barrel” shaped head of the horse femur on the left (a) is typical of running mammals. This shape is more common in nature and is similar to a cam hip in humans. It allows the hip to moves more forwards and backwards than in rotation. The more symmetrical and spherical head shape of the walrus femur on the right (b) is less common in nature and is seen in climbing and swimming mammals whose hips have more multidirectional rotation. (1)**





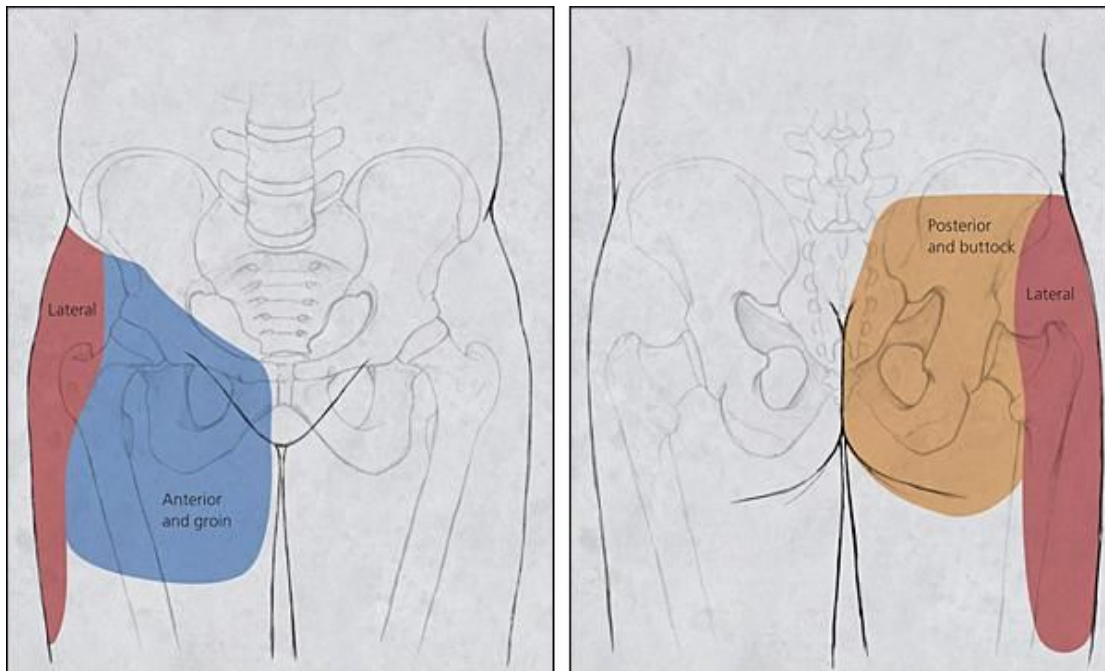
### Is the pain coming from the hip joint?

Pain arising from the **hip joint** itself is most commonly experienced in the groin. However, pain in the buttock, side of the hip (trochanteric region) and knee are also common. The pain can radiate down the thigh or upwards into the lower back.

Several conditions can cause pain in similar areas, such as pinched nerves in the lower back or buttock, herniae in the groin and muscle or tendon problems.

As it can be difficult to work out exactly where the pain is coming from in addition to clinical examination, xrays and CT/MRI scans your doctor may suggest an injection of local anaesthetic into the hip joint itself to see if this relieves your symptoms. If an injection helps, that is an indication that the problem lies in the hip joint and surgery may help. If the injection makes no difference, then it is unlikely that surgery will help, and it is better to keep investigating to find the real cause of the problem.

**Fig. 5. Location of pain related to hip joint. Anterior groin shown in blue, lateral or trochanteric shown in red, posterior, buttock, gluteal pain shown in orange. (2)**

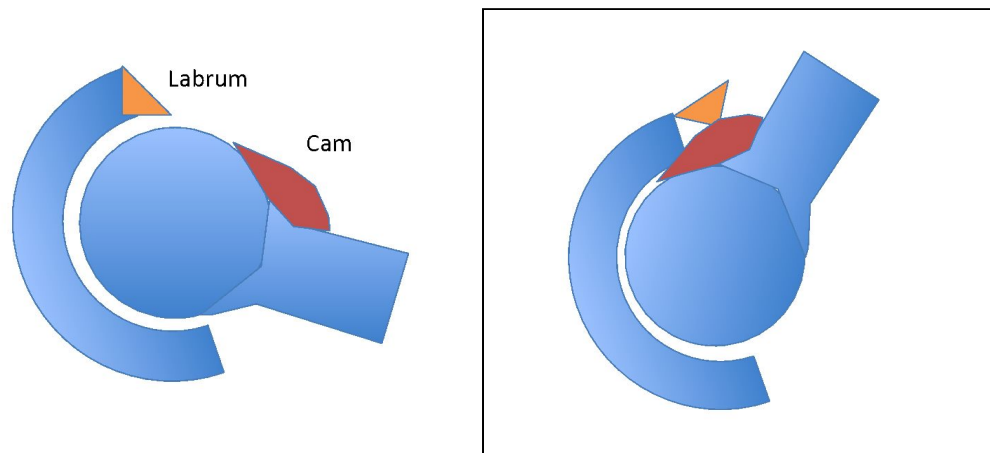


## Intra-articular causes of hip and groin pain

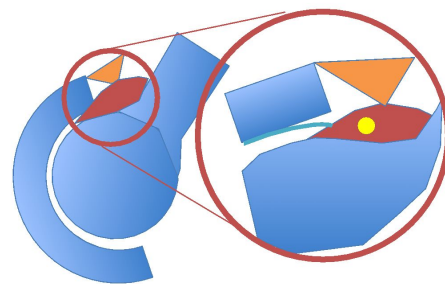
### 1. Impingement

Impingement is a clinical syndrome, where mismatch between the shape of the ball and socket cause pinching of the labrum in certain movements. Commonly, the head of the femur is not perfectly round (cam), and as it squeezes into the socket it pinches the labrum. Impingement can also be due to the rim of the socket overhanging if it is slightly too deep (pincer), or pointing slightly backwards (retroversion). The third type of impingement is a combination of both cam and pincer types, termed “mixed”. If the process of pinching at the rim of joint continues, damage can spread to the articular cartilage inside of the hip causing arthritis.

**Fig. 6 a. Axial view of cam impingement. Impingement occurs as aspherical femoral head or an overhanging bony acetabular rim pinches the soft acetabular labrum against the bony acetabular rim when the hip is moved into certain positions (6b). Typically when the hip is flexed forwards and rotated inwards.**



**Fig. 6 c & d. Repeated impaction of the cam against the labrum and acetabular rim can result in a labral tear at the junction between the labrum and the acetabular rim, and bony oedema and/or cyst formation in the cam lesion on the femoral neck as shown on the axial MRI in Fig 6c and in the axial schematic in Fig 6d. Eventually this process leads to damage to the articular cartilage, which may start to peel away from the chondro- labral junction (junction between the labrum and cartilage).**



*Non-operative treatment for Impingement*

The role of non-operative treatment is often underestimated. Physiotherapy in particular is very important. If the muscles around the hips get tight or weak, then they can cause the pelvis to tilt, making any pinching problems or socket problems worse. Core stability exercises to make sure the hip ball is always well centred in the socket are important (and also form an important part of recovery after surgery).

If you have never done any specific exercises for the hips, then this is always recommended as the first step, as any sports that only exercise the hips in one direction (like running which moves the hips mainly forwards and back, and not side to side) can result in muscles being out of balance, making the symptoms worse.

Physiotherapy focuses on strengthening the small but important muscles that keep the hip joint well centered in the socket and the spine stable above the pelvis, rather than big muscles that are used for running and jumping, which may be so strong and overdeveloped they are over powering the smaller important stabilising muscles.

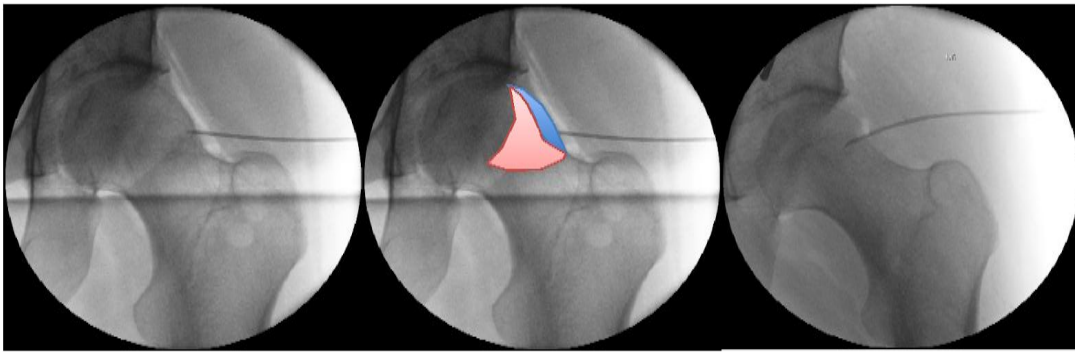
### *Surgery for Impingement*

The aim of surgery is to reshape the bones so that no more pinching of the labrum happens. This can be done either by open, or key-hole surgery (hip arthroscopy). To perform hip arthroscopy traction is used to partially dislocate the hip joint, just enough to insert a narrow camera and specialised instruments into the joint. Typically two to four small incisions are made. The areas of bone that are pinching the labrum are removed and the labrum is repaired or smoothed off (debridement).

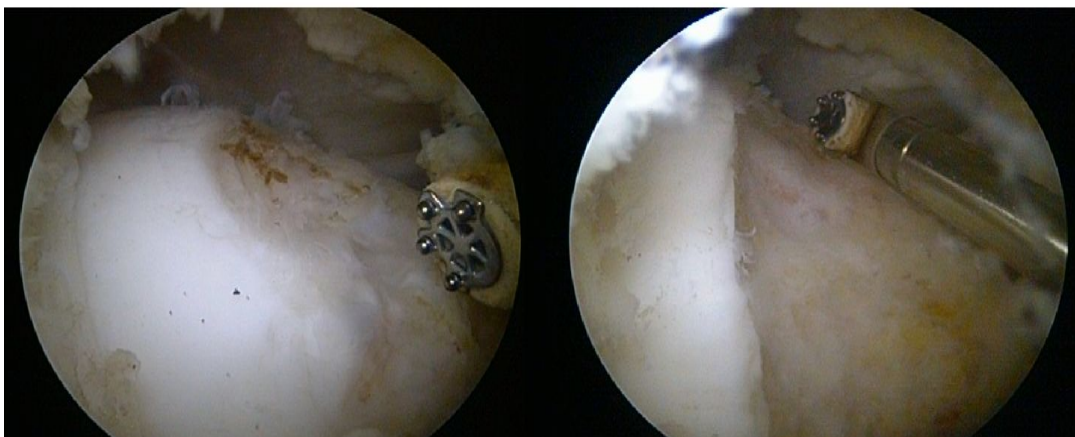If impingement is being caused by retroversion of the socket (socket pointing backwards and rim overhanging) it may be possible to address this from inside the joint using arthroscopy, however, if the orientation of the whole socket needs to be adjusted it may be necessary to perform an osteotomy as in dysplasia below.

**Fig. 7 a. Intra operative fluoroscopy (x-rays) of arthroscopic re-shaping of femoral cam deformity (osteochondroplasty). The area of bone removed superiorly is highlighted in blue. However, as symptoms are most commonly experienced when the hip is flexed, it is also very important to reshape the anterior portion of the cam, which is brought into contact with the rim of the socket when the hip is flexed forwards (highlighted in red). The surgeon can check during the operation that enough bone has been removed by moving**

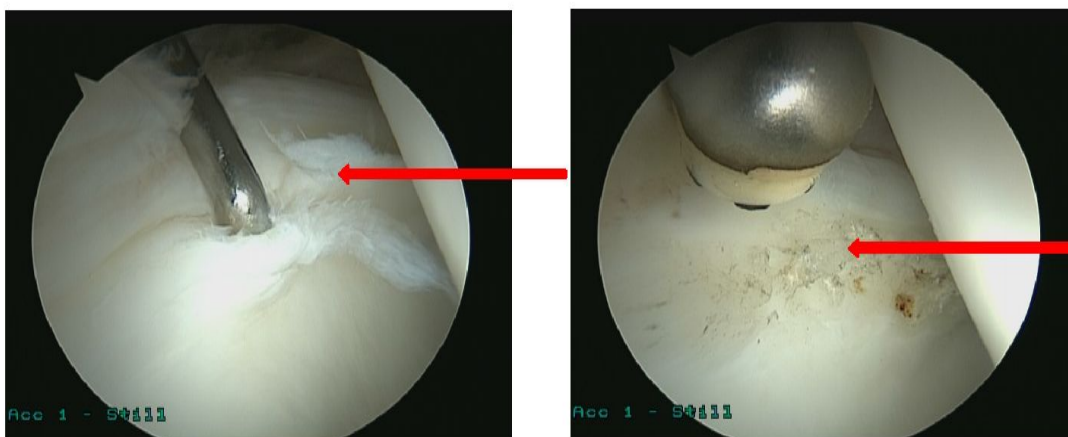
the hip around to test that there is enough clearance.



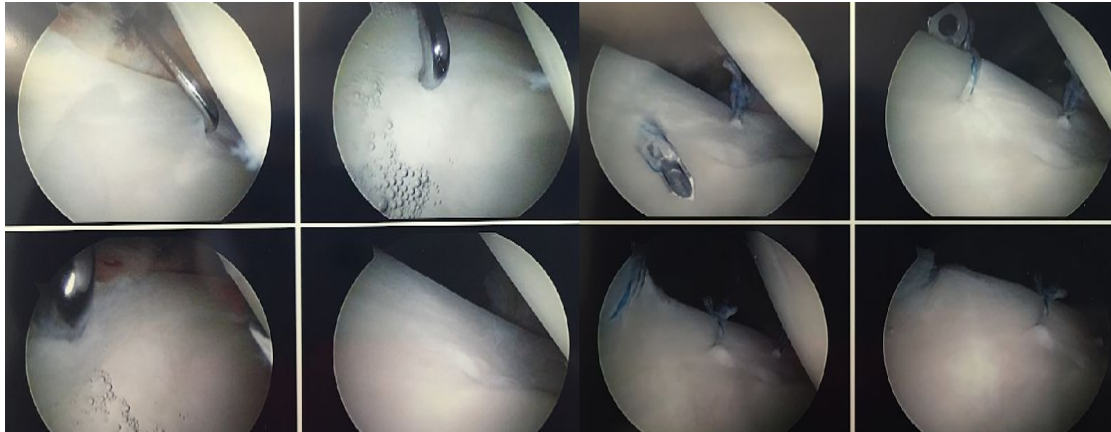
**Fig 7b. Intra-operative photographs of arthroscopic reshaping of femoral cam deformity**



**Fig 7 c. Intra-operative photographs of arthroscopic debridement of a labral tear using a radiofrequency probe to smooth way the torn fragments.**



**Fig 7 d. Intra-operative photographs of arthroscopic labral repair using suture anchors to refix the torn labrum to the bony rim of the acetabulum. Traction is applied to distract the joint and create space for specialized instruments.**



## **2. Dysplasia**

Dysplasia is a condition where the hip socket is too shallow or is pointing in the wrong direction. This results in not enough bony support in the weight-bearing zone of the hip and too much pressure falling on the rim (labrum), which can become torn or damaged. Many patients with shallow hips have excellent hip mobility and flexibility as the shallow socket allows more movement. However, the hip muscles have to work harder to keep the hip in the socket and many patients experience muscle fatigue and aching. When the hip socket is shallow the weight bearing area is smaller and over time the wear and tear concentrated in a small area can result in early arthritis.

### *Non-operative treatment for Dysplasia*

Often the symptoms of dysplasia are due to instability and physiotherapy exercises to strengthen the muscles that make sure the hip ball is well centred in the socket can help.

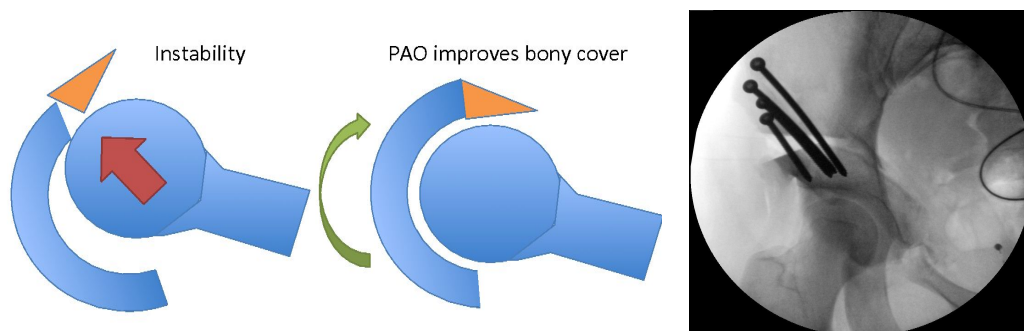
### *Surgery for Dysplasia*

Surgery for dysplasia can depend on how shallow the socket is. In milder forms, key-hole surgery to repair the labrum and tighten the capsule can improve

symptoms of instability and has been shown to have good short and medium term results in some patients.

When the socket is very shallow, key-hole surgery is no-longer recommended. In these cases **“Peri-acetabular Osteotomy”** is advised. This involves cutting around the socket (acetabulum), rotating it into the best possible position and fixing it in place with screws. “Peri-acetabular” means “around the acetabulum” and “osteotomy” comes from “osteo”, meaning “bone” and “otomy” meaning “cutting”. So translated literally the operation means: “Around the acetabulum bone cutting”. This has been shown to have good medium and long-term results.

**Fig. 8 a & b. Periacetabular osteotomy (PAO) is a technique that rotates the acetabulum around the head of the femur, providing more bony support where it is needed. This improves stability and increases the superior weight-bearing cartilage zone. Fig. 8d shows the initial position on intraoperative fluoroscopy (xrays).**

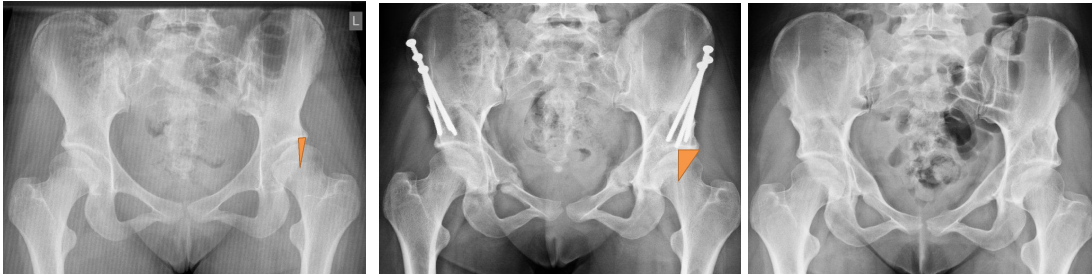

Many patients with dysplasia are referred because labral damage has been picked up on an MRI scan. However, the reason for this damage is the shallow socket. The important thing is to address the instability, which is the cause of the labral damage. Ideally this is by making the socket deeper and increasing the weight bearing area of the hip, which will take the pressure off the labrum and allow it to heal.

**Fig. 9 a. Pelvic X-ray of bilateral hip dysplasia illustrating the shallow socket and reduced bony support for the ball (femoral head) in the superior weight bearing part of the hip socket (orange zone). This increases the pressure on a small area of cartilage and on the labrum. Fig. 9 b. Shows increased size of the weight-bearing zone achieved by rotation of**



the acetabulum. The screws for initial stabilization remain in position. In Fig. 9 c the bony cuts in the pelvis have healed and the screws have been removed



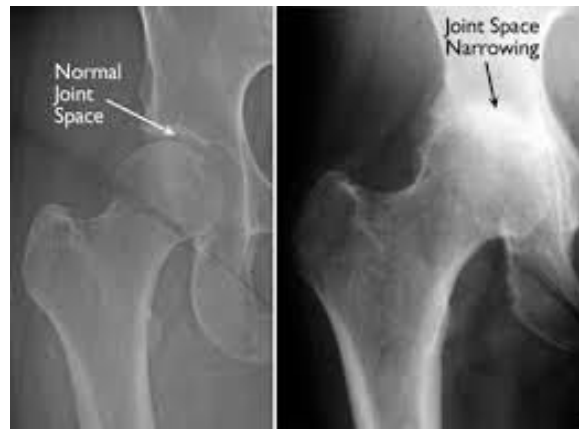### 3. Arthritis

Once there is established damage to the weight bearing cartilage surfaces inside the joint, this is referred to as **“osteoarthritis”**, or sometimes just as **“arthritis”**. If this has happened and the surfaces of the joint are already worn it is unfortunately not possible to repair the surface of the joint. In this situation it is important to consider the options carefully as the outcome of joint preservation surgery is less predictable.

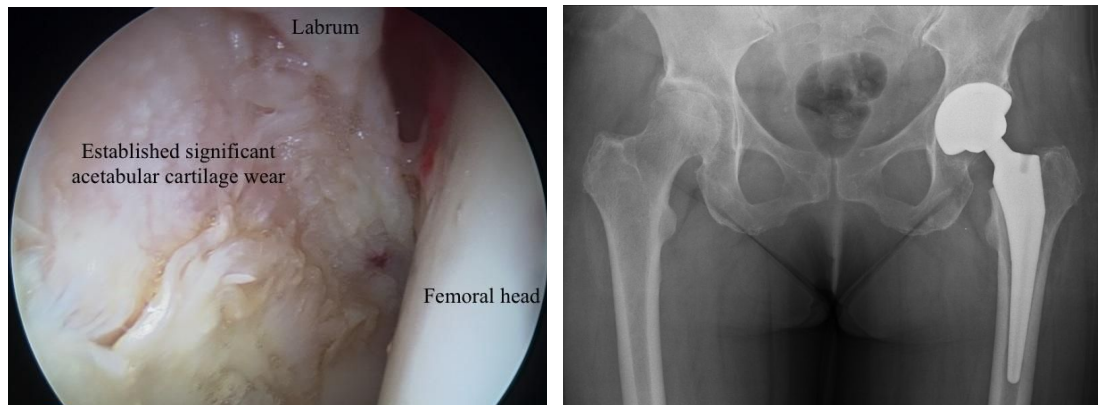
In the very early stages of arthritis hip preservation techniques may slow the progression. However, past a critical point hip preservation techniques can no longer help and in some cases can make symptoms worse. It can sometimes be difficult to judge exactly how advanced the arthritic changes are before surgery. To minimize surprises we encourage a detailed discussion of expectations before surgery in every case. For some patients hip replacement may be the best option.

**Fig 10a. Xray of the pelvis showing joint space narrowing, osteophytes, subchondral sclerosis and cysts, the cardinal features of osteoarthritis.**





**Fig. 10b** Intraoperative hip arthroscopy photograph showing changes of osteoarthritis with significant articular cartilage damage on the acetabular side. **Fig. 10 c.** Hip replacement X Ray.



## **Extra-Articular Causes Of Hip Pain**

### *1. Trochanteric Pain Syndrome*

Trochanteric pain syndrome is a term used to describe painful conditions around the outer aspect of the hip (See figure 5). It may be caused by inflammation of the trochanteric bursa, gluteus medius or minimus tendinopathy or other inflammatory conditions of the hip. Sometimes overload of the tendons in this area can be due to an underlying problem with the hip joint, such as dysplasia and the hip should be fully assessed to exclude an intra-articular cause. The mainstay of treatment for trochanteric pathology is physiotherapy sometimes combined with injections.

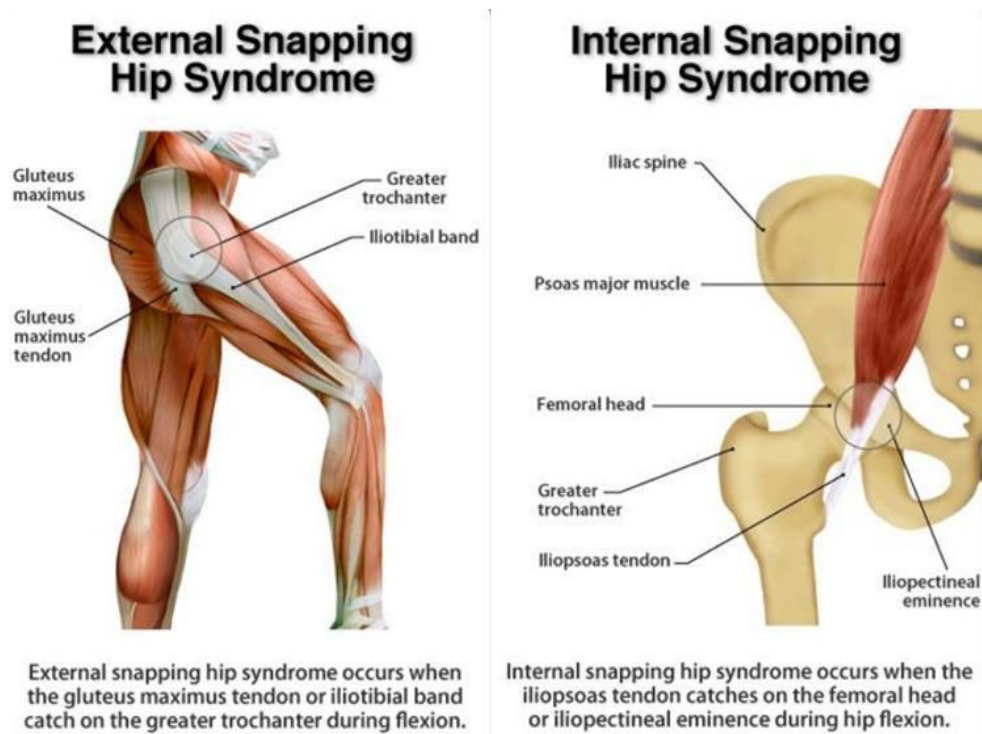
Occasionally, key-hole surgery to repair the gluteus tendons or to address bone spurs or inflammation associated with bursitis and tendinopathy are necessary.

## 2. Snapping Hip Syndrome

Most “snapping” or “popping” around the hip is due to tendons being pulled tight over a bony protuberance and then releasing. In the hip there are three main types.

1. In “external” snapping hip, the iliotibial band slips over the outside of the greater trochanter. This can also be a cause of trochanteric pain syndrome.
2. In “internal” snapping hip, the iliopsoas tendon slips over the ileopectineal eminence in the groin.

**Fig 11. Extra-articular causes of snapping hip syndrome**



3. “Intra-articular” snapping hip may be due to articular cartilage damage, a loose body or a torn labrum.

A full assessment of the hip is recommended to exclude intra-articular causes. Most extra-articular snapping resolves with physiotherapy to stretch and strengthen the

tight muscles. Occasionally injections or key hole surgery are required to remove bone spurs or release tendons. For intra-articular causes, surgery may be required.

#### *4. Deep Gluteal Pain Syndrome*

Patients with this condition present with buttock pain, which may radiate along the back of the thigh. Again it is important to assess the hip fully and exclude intra-articular causes. As the symptoms mimic sciatica, back problems also need to be excluded. This syndrome is commonly caused by pinching of the sciatic nerve, by tight muscles and tendons in the buttock area. It may also be due to piriformis tendonitis, hamstring tendinopathy or inflammation of other tissue in that region.

Most of these conditions improve with physiotherapy alone but some patients may require injections. For patients with longstanding problems surgical treatment may be beneficial. The type of surgery would depend on the cause of the problem.

#### *5. Adductor Tendonitis and Pubic Symphsitis*

Inflammation of adductor tendons can cause groin pain. They are common in runners and athletes and difficult to distinguish from pain arising from hip joint. Once again a full assessment is recommended. Most cases resolve with physiotherapy and/or injections.

#### *6. Sports injuries*

Avulsion injuries of the tendons around the hip may occur during sports and athletic activities. Specifically, avulsion of the rectus femoris, adductor tendons or hamstring tendons. Surgical repair may be required in some patients.

### **Conclusions**

Many conditions can cause pain in and around the hip joint in adults. Early and thorough assessment is recommended, particularly in younger adults, to determine the cause and to enable hip preservation surgery to be carried out when indicated.

## References

1. Hogervorst T. Osteoarthritis: a consequence of evolution? Bone Jt 360 [Internet]. 2012 Feb 1 [cited 2018 Feb 14];1(1):2–6. Available from: <http://www.bj360.boneandjoint.org.uk/cgi/doi/10.1302/2048-0105.11.360002>
2. American Academy of Family Physicians. JJ, Furukawa M. American family physician. [Internet]. Vol. 89, American Family Physician. American Academy of Family Physicians; 1970 [cited 2018 Feb 14]. 27-34 p. Available from: <https://www.aafp.org/afp/2014/0101/p27.html>